

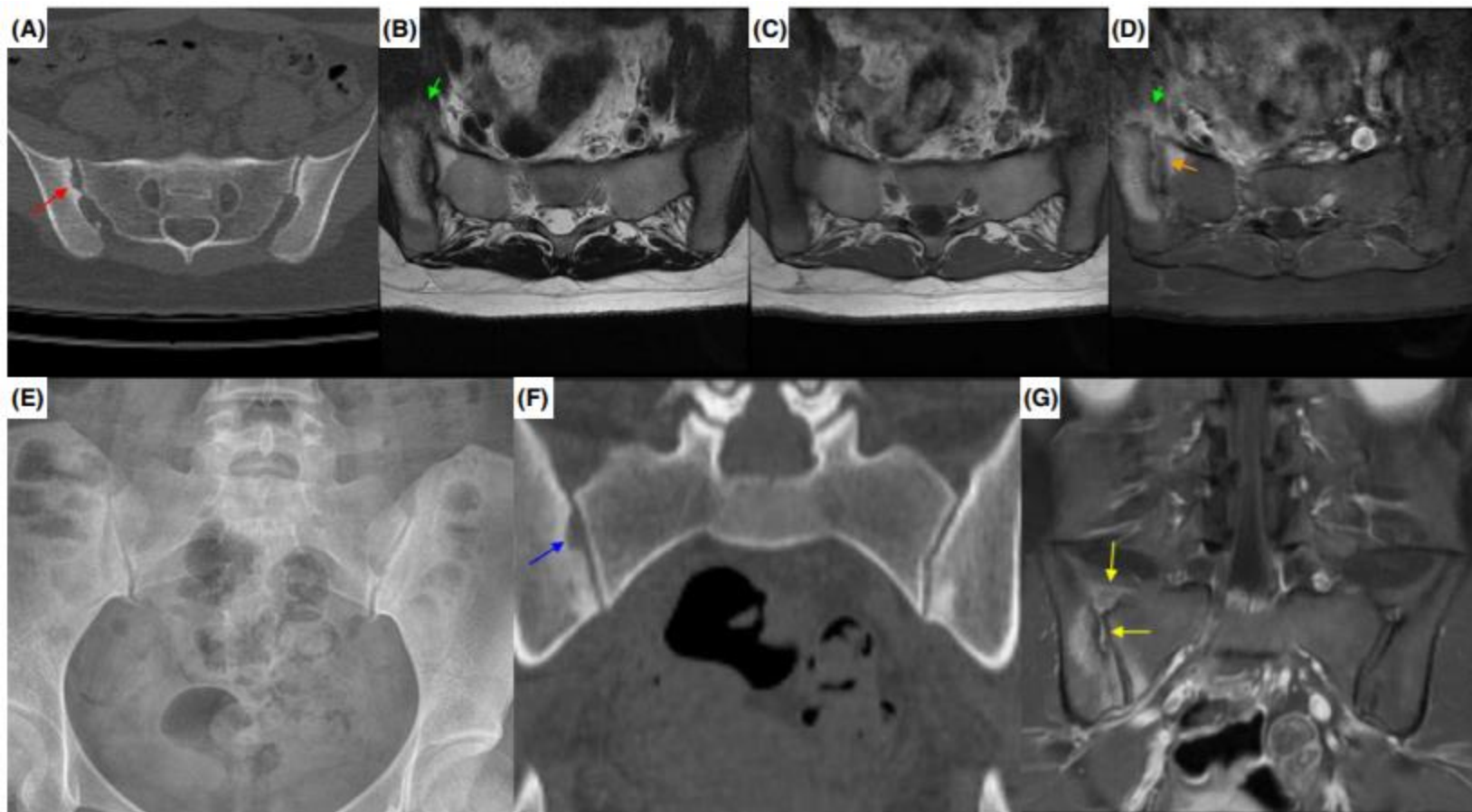
Rt. ipsilateral buttock pain in
a 27-year-old patient

Min Cheol Chang

- F/27
- Rt. ipsilateral buttock pain (Numerical Rating Scale [NRS] = 3)
- Progressively increased in severity over 6 months

P/E

- Patrick and sacral thrust tests +/-
- Motor and sensory: intact
- SLRT f/f



Lab

- CRP = 0.27 mg/dl
- WBC = 6260 cells/ μ l
- ESR = 31/mm/h
- HLA-B27 negative

Treatment

- Meloxicam 15 mg once daily
: the patient's pain almost completely resolved.

Diagnosis

- We diagnosed the patient's condition as axial spondyloarthritis (SpA)

However

- 10 months after initial onset, the pain recurred (NRS = 7) and could not be controlled by oral medication.